

This text is a translation from the original German which should be used for referencing. The German version is authoritative.

CASE REPORT

From Baghdad to Regensburg

The treatment of a US soldier with life threatening injuries using a new system for extracorporeal, pump free pulmonary support

Thomas Bein, Alois Philipp, Warren Dorlac, Kai Taeger, Michael Nerlich, Hans J. Schlitt

SUMMARY

History and clinical findings: The authors describe a new extracorporeal pumpless interventional lung assistance system (iLA) which was inserted in a young US soldier suffering from severe acute respiratory distress syndrome with critical hypoxemia/hypercapnia after blast injury in Baghdad. The system is characterized by a new membrane gas exchange system with optimized blood flow which is integrated in an arterial-venous bypass established by cannulation of the femoral artery and vein. After implementation of the system, gas exchange improved rapidly, and the patient was airlifted from Iraq to Regensburg University Hospital, where he recovered gradually. **Treatment and clinical course:** The system was removed after 15 days, and the patient was successfully weaned from mechanical ventilation. **Discussion:** iLA serves as an enabling device for artificial lung assistance with easy use and low cost. However, bleeding complications and ischemia of the lower limb can occur as a consequence of wide bore cannulation of the femoral artery. Further prospective studies are needed to establish whether iLA can be adopted more widely. *Dtsch Arztebl 2006; 103(42): A 2797–2801.*

Key words: acute respiratory distress syndrome, blast injury, lung protective ventilation, pumpless extracorporeal interventional lung assist

Even after the end of the war in Iraq frequent casualties are being suffered in the civilian population and in the military, due to constant attacks, insurgency and acts of terrorism. Despite appropriate equipment and extreme caution, allied soldiers find themselves in traps, or the object of suicide attacks. Survivors frequently suffer grave injuries requiring immediate surgical treatment and intensive care. However, facilities for invasive organ replacement techniques such as extracorporeal pulmonary or renal support are limited, as are facilities for transferring unstable, critically wounded patients on long haul flights to Europe or the United States. The authors report the case of a 22 year old American soldier, who was very seriously wounded in an explosive attack. Using a new, extracorporeal pulmonary support system developed at the University Hospital of Regensburg in cooperation with a commercial company, the patient was able to be transferred to the authors' hospital and treated successfully.

Chronology of the attack and the transfer

During a patrol in convoy through Baghdad, the US sergeant's tank crossed two explosive devices. They detonated and tore into the base of the tank. The soldier suffered a traumatic amputation of both lower legs. He was transferred in a conscious and responsive condition from the vehicle and resuscitated. In view of the massive arterial blood loss from the stumps tourniquets were applied below the knees and circulatory volume generously replaced. Intubation became necessary as the patient complained of increasing shortness of breath. On reaching the military hospital, he received further stabilization and diagnosis. The following injuries were documented:

- severe, rapidly developing pulmonary failure (ARDS, "acute respiratory distress syndrome") as a consequence of the explosion trauma
- acute abdominal trauma (free fluid on ultrasound)
- laceration to the liver parenchyma
- Bilateral renal contusion

Klinik für Anästhesiologie, Universitätsklinikum Regensburg (Prof. Dr. med. Bein, Prof. Dr. med. Taeger); Klinik für Herz-, Thorax- und herznahe Gefäßchirurgie, Universitätsklinikum Regensburg (Philipp); Landstuhl Regional Medical Center, Division of Trauma and Surgery, Landstuhl (Dr. med. Dorlac); Abteilung für Unfallchirurgie, Universitätsklinikum Regensburg (Prof. Dr. med. Nerlich); Klinik für Chirurgie, Universitätsklinikum Regensburg (Prof. Dr. med. Schlitt)

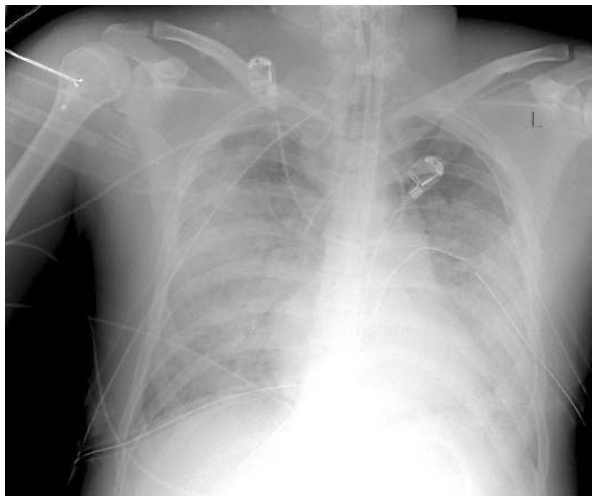

Figure 1: Chest X-ray following explosion trauma: diffuse, widespread opacification, affecting almost all lung areas (Institut für Röntgendiagnostik, Universitätsklinikum, Regensburg).

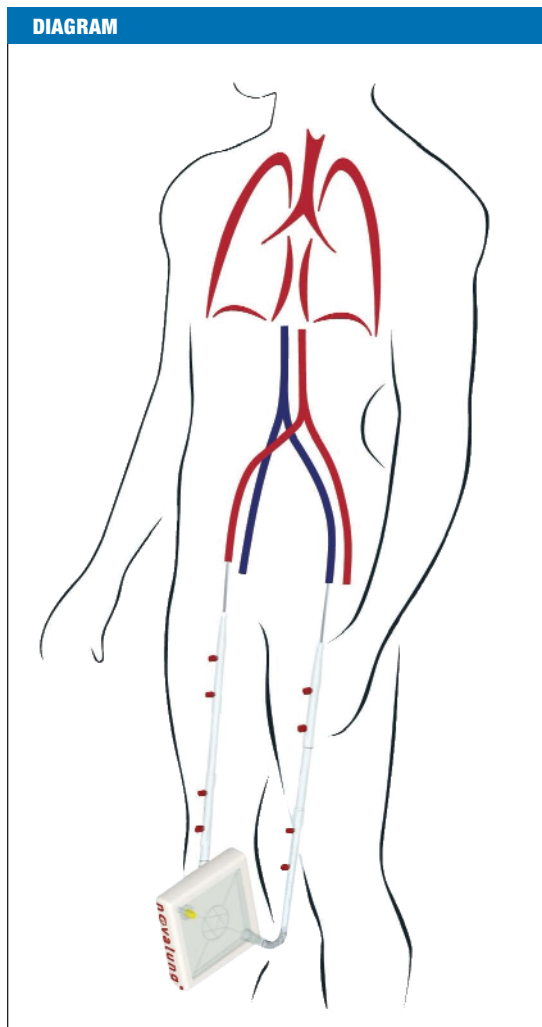
- traumatic amputation of both lower legs
- hemorrhagic shock.

Immediate management included wound debridement, stump hemostasis, and an exploratory laparotomy and packing of the liver trauma with swabs. During this procedure massive transfusion of blood products was necessary. Because of the danger of an abdominal compartment syndrome, the abdomen was extended without tension using vicryl netting. The patient was then stabilized on the intensive care unit. Over the following 48 hours, however, he developed acute renal failure ("crush kidney"), and the acute pulmonary failure progressed rapidly. It became increasingly difficult to secure pulmonary gas exchange, despite constant increases in the invasiveness of ventilation via increasing maximum ventilatory pressures, tidal volume and positive end expiratory pressure (PEEP).

The chest X-ray had the appearances of severe ARDS with diffuse opacification affecting almost all lung areas (*figure 1*). The ventilation settings and the resulting blood gas values suggested hypoxic and hypercapnic decompensation even with the maximal ventilatory support available under the prevailing conditions (*table*), which is only treatable using extracorporeal pulmonary replacement. Neither this, nor pump based renal replacement, such as hemodialysis, were available in Baghdad. In this critical situation, the use of a new, pump free extracorporeal system of pulmonary replacement, whose use had been reported in a number of studies (1, 2, 3, 7), was considered. Although "Food and Drug

TABLE		
Ventilation and blood gas values before and after implantation of the interventional pulmonary support system (iLA)		
	before iLA	after iLA implantation
FIO ₂	1.0	0.85
PaO ₂ (mm Hg)	40	90.1
SaO ₂ (%)	77	92
PaCO ₂ (mm Hg)	58	36.9
PEEP (cm H ₂ O)	15	13
RR/min	28	26
V _T (mL)	400	390
MV (L/min)	11.2	10.1
P _{insp} (cm H ₂ O)	38	32

FIO₂, fractional inspiratory oxygen concentration; PEEP, positive end expiratory pressure; RR, respiratory rate/minute; V_T, tidal volume; MV, minute volume; P_{insp}, maximal inspiratory pressure



Schematic representation of the interventional pulmonary support system, to which is attached an O₂ supply (yellow stopper). (modified from a scientific diagram courtesy of Fa. Novalung, Hechingen, Germany)

Administration" (FDA) approval was lacking, the medical administration of the US forces had taken an interest in this method and ordered a number of units.

Technical data

The system of extracorporeal, interventional pulmonary assistance (iLA, "interventional lung assist", manufactured by Novalung, Hechingen, Germany) is perfused by the patient's circulation without the use of a mechanical blood pump: After cannulation of the femoral artery and vein, the arterial pressure gives rise to a passive shunt, into which a membrane lung is introduced (*diagram*). The heart is the driving force.

ILA is a pulmonary support method requiring only a source of oxygen without further technical equipment or energy. The gas exchange membrane (folded surface area = 1.3 m²) is the central element of the system. It is characterized by a low resistance relative to the blood flow directed across it. The development of a new diffusion membrane made of poly-(4-methyl-1-pentene) has made it possible to reach a sufficiently high blood flow rate with a driving pressure difference of around 70 mm Hg (femoral artery – femoral vein). The precondition is cardiovascular stability, since an adequate shunt flow (1,5 L/min) requires a mean arterial pressure of at least 70 mm Hg.

Procedures

After large bore cannulation (13-17 gauge) of the femoral artery and vein using a Seldinger technique, the gas exchange system, already filled with crystalloid, is connected. Prior to this 5 000 I.U. Heparin are given intravenously. Afterwards the arteriovenous shunt is released. A continuous flow of gas – up to around 12 L O₂/min – is successively insufflated

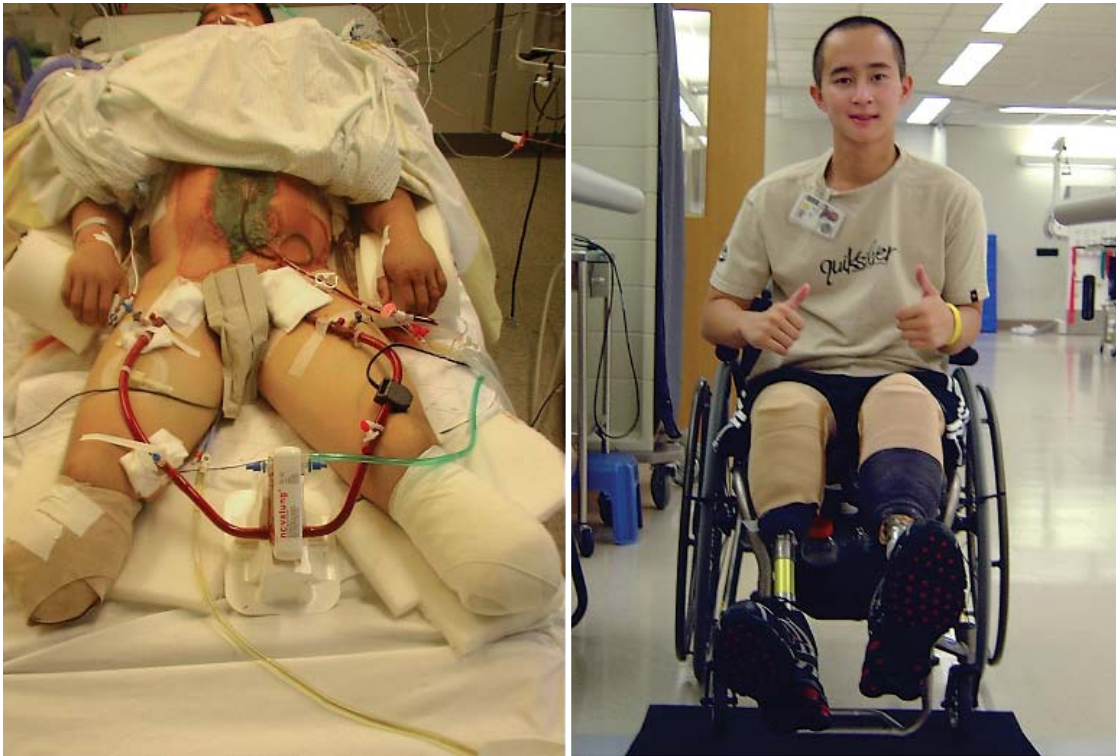


Figure 2:

- a) Admission on arrival in Regensburg. The iLA system with its gas exchange membrane in a box is visible, along with the ultrasound clip for the measurement of blood flow.
 b) The patient in rehabilitation after fitting with prostheses.
 (photographs used with patient's permission)

into the gas exchange system, which both oxygenates the flowing blood and effectively "blows off" carbon dioxide. The system requires no further maintenance after starting. The whole system is heparinized. For continuous use, a continuous low dose heparin infusion (200-600 I.E./h) is sufficient, with the aim of a mild prolongation of the activated partial thromboplastin time (APTT) to around 50 seconds. The shunt flow can be measured moment by moment online using Doppler ultrasound.

After successful treatment of the pulmonary failure the cannulae are withdrawn, after checking that clotting is adequate, and firm pressure is applied to the puncture site for about 30 minutes. Pressure dressings help prevent significant secondary bleeding.

Implantation of the iLA system and follow up

In this critically wounded, hypoxic, hypercapnic patient, the iLA system was successfully connected, following cannulation. Immediately following implantation oxygenation increased markedly, and carbon dioxide elimination improved (*table*). As staff had no prior experience with the iLA system, the patient was first stabilized and then transferred on day 5 first with military transport plane to Landstuhl, and from there by helicopter to the intensive care unit of Regensburg university hospital. The long distance travel was unproblematic and uncomplicated, requiring only a portable ventilator and oxygen cylinders for the iLA system. The authors took over care of the patient in a critical and restricted but stable condition (*figure 2 a*). The soldier was given inotropes for increased support. His renal function was markedly impaired both qualitatively and quantitatively, so continuous pump driven hemodiafiltration was commenced.

The problem of the open abdomen was addressed via a repeat exploratory laparotomy, carried out on the intensive care unit, but yielded no findings indicating further treatment. The stump wounds were extensively debrided, and a heavy growth of *acinetobacter baumannii* found on microbiological examination. This organism was also isolated from the lungs via broncho alveolar lavage. The authors continued the antibiotic treatment with meropenem, levofloxacin and fluconazole which had been commenced in Baghdad.

Thanks to the efficient gas exchange afforded by the iLA system, the aggressivity of ventilation was able to be reduced considerably. The ARDS resolved gradually.

Over the following days the patient became visibly more stable. The abdomen was closed definitively, and the clinical, radiologic and laboratory signs of infection continued to resolve. The iLA process was discontinued after 15 days and the cannulae removed uneventfully. The patient was extubated a few days later, with satisfactory gas exchange with spontaneous breathing. The US soldier was transferred to the military hospital in Landstuhl, and from there to an army rehabilitation center in California. There he made a swift recovery and was fitted with prostheses (*figure 2 b*).

The key to this patient's successful treatment was a combination of extensive surgical and intensive care strategies. In addition to the extracorporeal pulmonary replacement, swift and successful surgical treatment (wound management of the infected stumps), renal replacement therapy and close management of the circulatory volume via a pulmonary wedge catheter played an important role.

Discussion

Adult respiratory distress syndrome (ARDS) is characterized by a massive release of inflammatory mediators in the lung, followed by interstitial and alveolar edema and marked parenchymal instability (tendency to collapse, atelectasis [4]). In its advanced stages a morphologic destruction of the alveolar structure occurs, with scarring and fibrosis of the connective tissue.

ARDS manifests clinically as a critical disturbance of pulmonary gas exchange with hypoxia/hypercapnia. Mechanical ventilation is the treatment of choice, but the frequently necessary high ventilation pressures can cause further damage via ventilation induced cyclical overextension of already damaged alveoli (VILI, "ventilator-induced lung injury") (5).

For this reason extracorporeal pulmonary replacement (ECMO) has been advocated in these cases for the last 20 years, and developed in specialist centers. The aim is to achieve adequate oxygenation and decarboxylation via extra pulmonary gas exchange, as well as to rest the lung and allow it a chance to heal (4). ECMO allows more effective oxygenation and CO₂ elimination. This method has also been used during the inter hospital transfer of critically ill patients. ECMO requires a high level of technical and staff support, and exposes patients to the anticoagulation-related risk of bleeding. Nevertheless, in the worst case scenario, ECMO remains the treatment of choice.

The authors have developed and reported the use of extracorporeal pulmonary support (iLA) in recent years as an alternative treatment. Through the implantation of an arterio venous bypass, into which a new gas exchange membrane with favorable flow properties is incorporated, it is possible to do without a pump based system with all its technical requirements. iLA allows rapid and effective elimination of carbon dioxide and a moderate increase in oxygenation. It is useful not only as a means of reducing the need for aggressive ventilation, but during inter hospital transfer of critically ill patients (6). However, the transport of such patients requires a clinical team equipped to deal with all emergencies. Another use of iLA which has been described is in bridging the time gap while waiting for a lung transplant (7). Indications, effects and complications are displayed in the box.

The authors report of the use of this system in a young soldier with severe ARDS following explosion trauma, who, had he remained in the military hospital in Baghdad would probably have died. But transfer without extracorporeal pulmonary support would itself have exposed the patient to an unacceptably high risk of further blood gas deterioration.

As with all medical interventions, the use of iLA is not without risk and unwanted effects: the large bore cannulation of the femoral artery carries the risk of critical ischemia of the distal limb, especially where the history suggests there may be vessel wall damage, such as in peripheral vascular disease. In addition, there is a possibility of significant bleeding during or following cannulation, albeit with no reported deaths from this complication. In 90 uses of this system in ARDS patients reported by the Authors (8), 9 (10%) showed a critical under perfusion requiring cannula removal.

From 2003 the authors have routinely measured vessel diameter prior to cannulation, and matched cannula gauge to vessel size (15-17 gauge). This measure appears to have reduced the incidence of critical ischemia. Still, the risks of arterial cannulation, bleeding and

BOX

Indications, effects and complications of the interventional, extracorporeal pulmonary support system (8)

Indications

- severe pulmonary failure due to:
 - trauma
 - pneumonia
 - sepsis
 - aspiration
 - drowning
 - peritonitis
 - pancreatitis
- "bridging to lung transplant"

Effects

- increase in oxygenation
- increase in CO₂ elimination

Possible complications

- lower limb ischemia (cannulation)
- bleeding during cannulation
- bleeding after cannula removal

critical under perfusion remain a weakness of this treatment. In addition to the use of newer cannulae with a smaller outer diameter (iLA II), this technique requires careful case selection, an experienced practitioner, and close monitoring on the intensive care unit via pulse oximetry of the cannulated extremity, and observation of the circulation.

It should be noted that this procedure is sufficiently experimental that its role is not yet reliably established. For this reason, its use is currently restricted to specialist centers.

Interventional, extracorporeal pump free pulmonary support opens up new possibilities for pulmonary protection. Experiences to date are encouraging, although randomized studies are lacking, and the procedure carries significant risks, especially in the learning phase. Both technical improvements and robust studies in larger populations are needed.

Conflict of Interest Statement

Prof. Bein has received honoraria for lectures from Novalung, Hechingen, Germany. The other authors declare no conflicts of interest, in the terms of the International Committee of Medical Journal Editors.

Manuscript received on 22 March 2006, final version accepted on 11 July 2006.

Translated from the original German by Dr. Sandra Goldbeck-Wood.

REFERENCES

1. Reng M, Philipp A, Kaiser M, Pfeifer M, Grüne S, Schölmerich J: Pumpless extracorporeal lung assist and adult respiratory distress syndrome. *Lancet* 2000; 356: 219–20.
2. Liebold A, Reng CM, Philipp A, Pfeifer M, Birnbaum DE: Pumpless extracorporeal lung assist – experience with the first 20 cases. *Eur J Cardiothorac Surg* 2000; 17: 608–13.
3. Bein Th, Prasser C, Philipp A, Müller T, Weber F, Schlitt HJ et al.: Pumpenfreie extrakorporale Lungenunterstützung mit arteriovenösem Shunt beim schweren akuten Lungenversagen des Erwachsenen. *Anaesthesist* 2004; 53: 813–9.
4. Ware LB, Matthay MA: The acute respiratory distress syndrome. *N Engl J Med* 2000; 342: 1334–49.
5. Lionetti V, Recchia F, Ranieri M: Overview of ventilator-induced lung injury mechanisms. *Curr Opin Crit Care* 2005; 11: 82–6.
6. Zimmermann M, Bein T, Philipp A, Ittner K, Foltan M, Drescher J et al.: Interhospital transportation of patients with severe lung failure on pumpless extracorporeal lung assist. *Br J Anaesth* 2006; 96: 63–6.
7. Fischer S, Simon AR, Welte T, Hoepfer MM, Meyer A, Tessmann R et al.: Bridge to lung transplantation with the novel pumpless interventional lung assist device NovaLung. *J Thorac Cardiovasc Surg* 2006; 131: 719–23.

This text is a translation from the original German which should be used for referencing. The German version is authoritative.

8. Bein Th, Weber F, Philipp A, Prasser Ch, Pfeifer M, Schmid FX et al.: A new pumpless extracorporeal interventional lung assist in critical hypoxemia/hypercapnia. Crit Care Med 2006; 34: 1372–7.

Corresponding author

Prof. Dr. med. Thomas Bein, Klinik für Anästhesiologie
Universitätsklinikum Regensburg
93042 Regensburg, Germany
thomas.bein@klinik.uni-regensburg.de