

Clinical Rating Scale for Oral GVHD

Mark M. Schubert
Jane Fall-Dickson

Oral GVHD scoring schema

	LIPS		LABIAL MUCOSA		BUCCAL MUCOSA		TONGUE		PALATE
	Lower	Upper	Lower	Upper	Right	Left	Dorsal	Latero-ventral	Soft
Erythema									
Lichenoid Hyperkeratosis									
Pseudomembrane/ Ulceration									

Total OMRS Score: _____ (possible range 0 – 81; sum all items)

Instructions for Rating:

Erythema

0 = Normal/No change 1 = Mild redness 2 = Moderate redness 3 = Severe redness (color of fresh oxygenated blood)

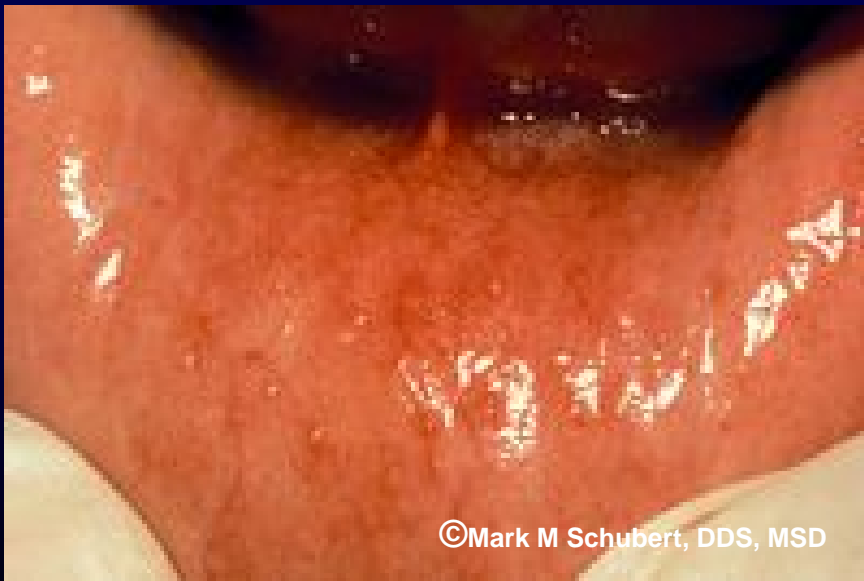Lichenoid Hyperkeratosis and Ulceration/Pseudomembrane

0 = None 1 = > 0 but ≤ 1cm² 2 = 1 cm² but ≤ 2 cm² 3 = > 2cm²

MUCOCELES

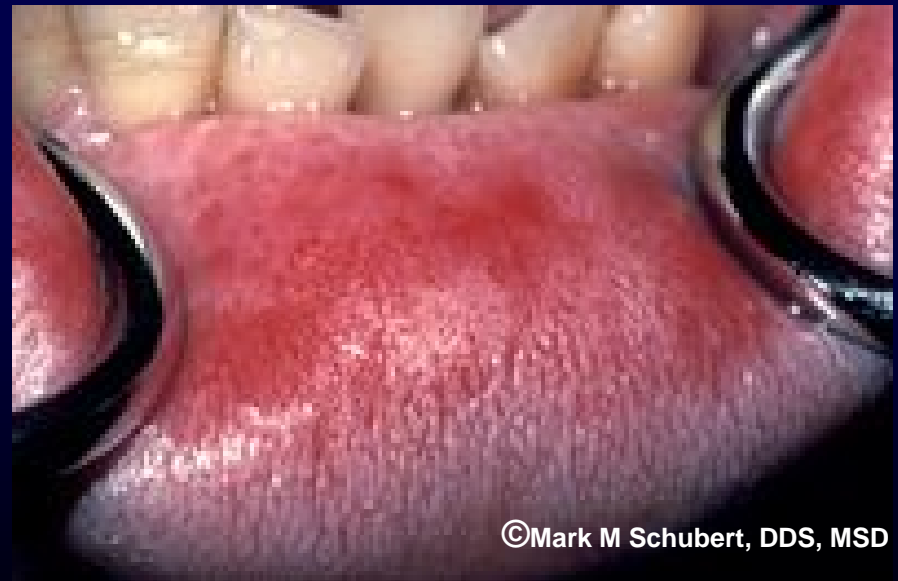INSTRUCTIONS: Assess each indicated oral cavity location for mucoceles and mark present/absent (X).

	Present	Absent
Soft Palate		
Lower Labial Mucosa		
Buccal Mucosa		



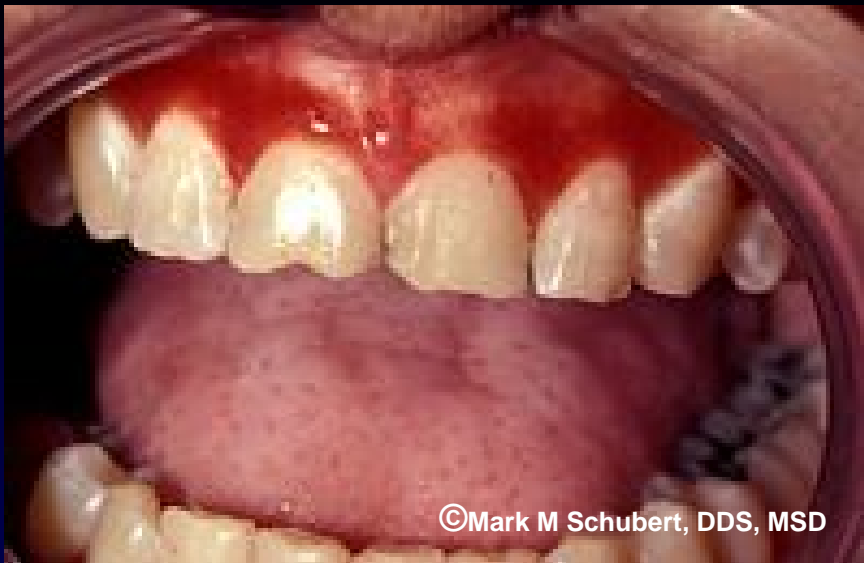©Mark M Schubert, DDS, MSD

Mild Erythema



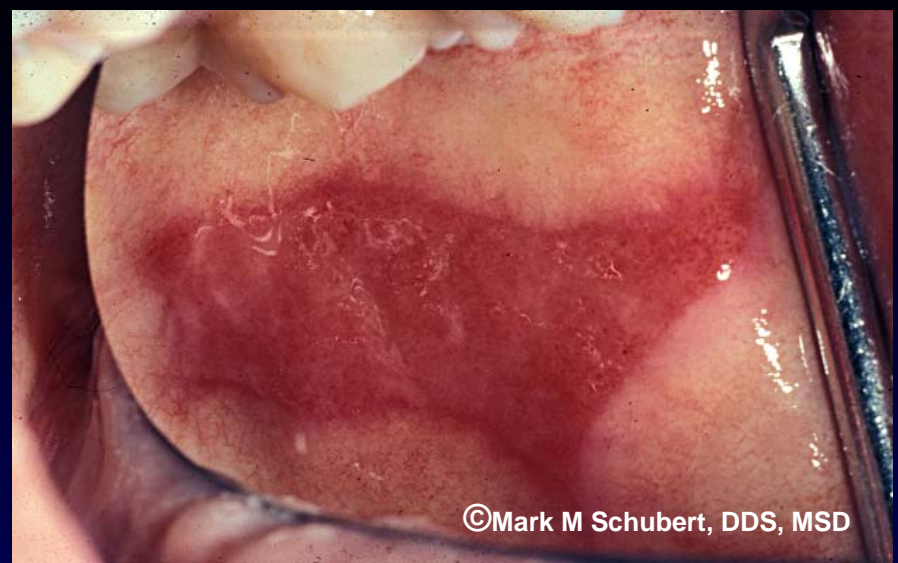©Mark M Schubert, DDS, MSD

Moderate Erythema



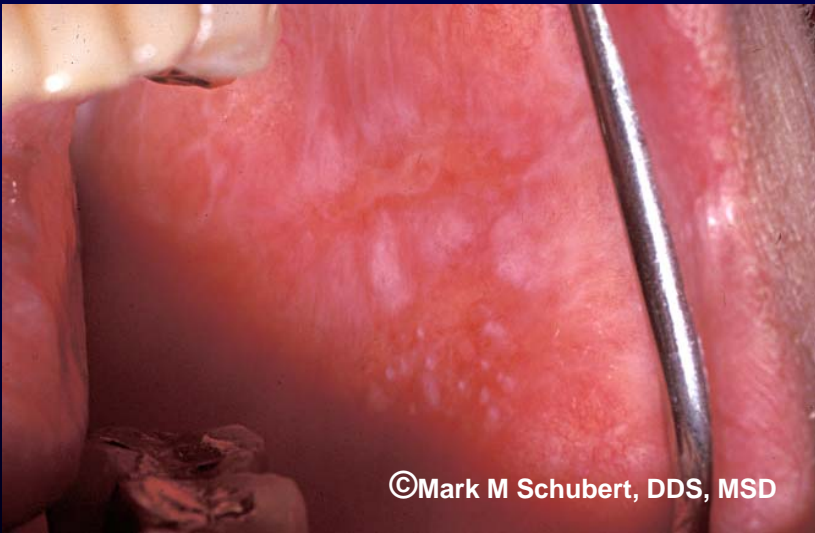
©Mark M Schubert, DDS, MSD

Severe Erythema

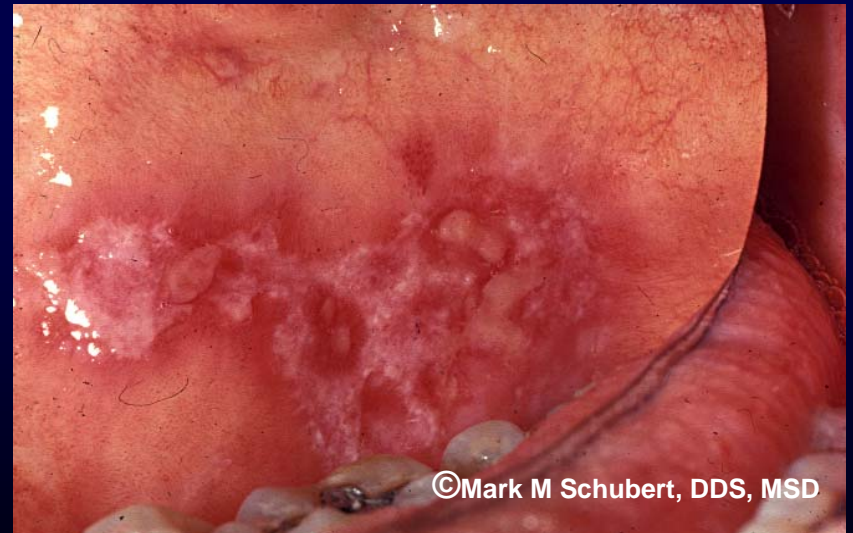

©Mark M Schubert, DDS, MSD

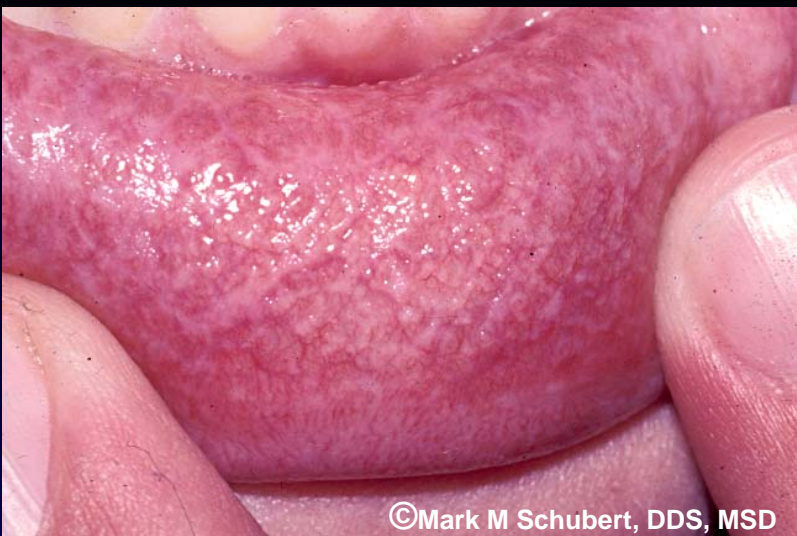Severe Erythema



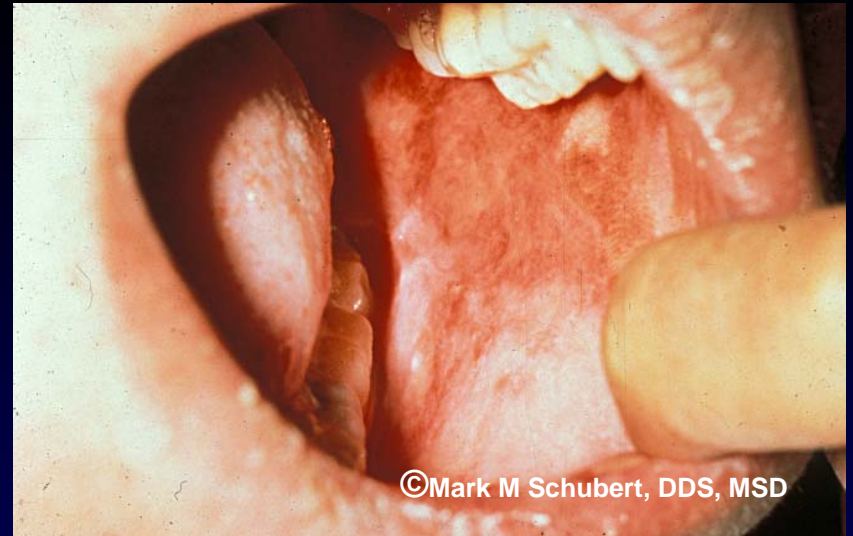
Lichenoid Hyperkeratosis

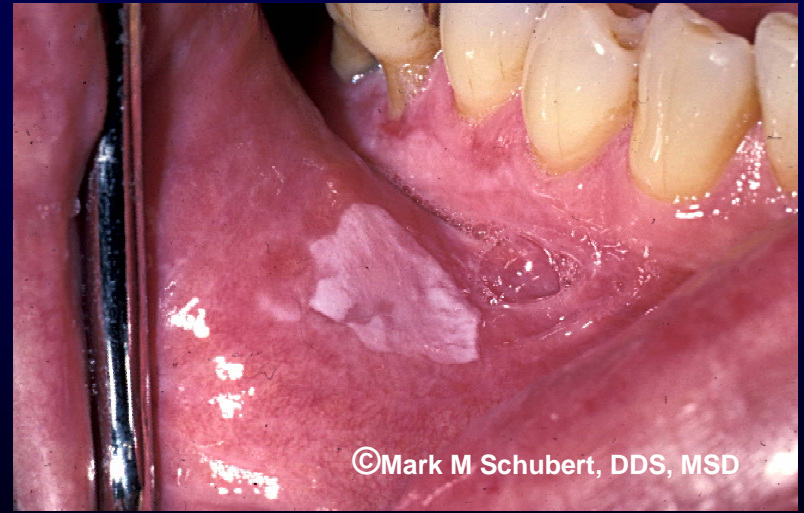
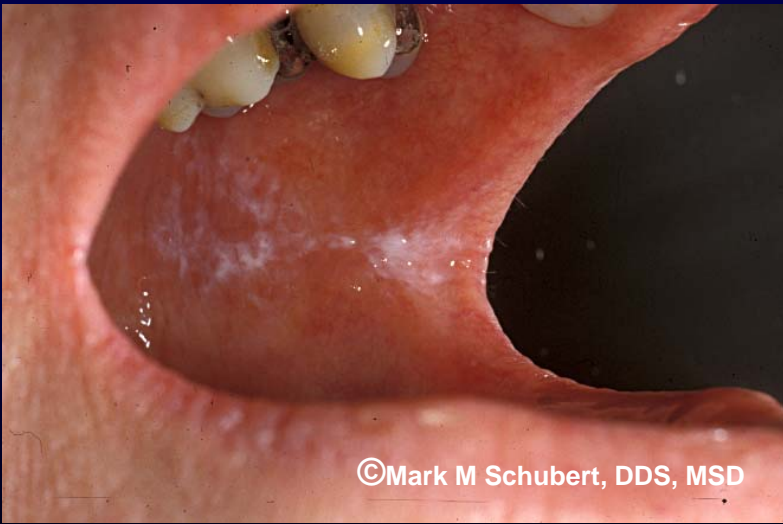

**Lichenoid Hyperkeratosis
(with pseudomembranous ulcerations)**

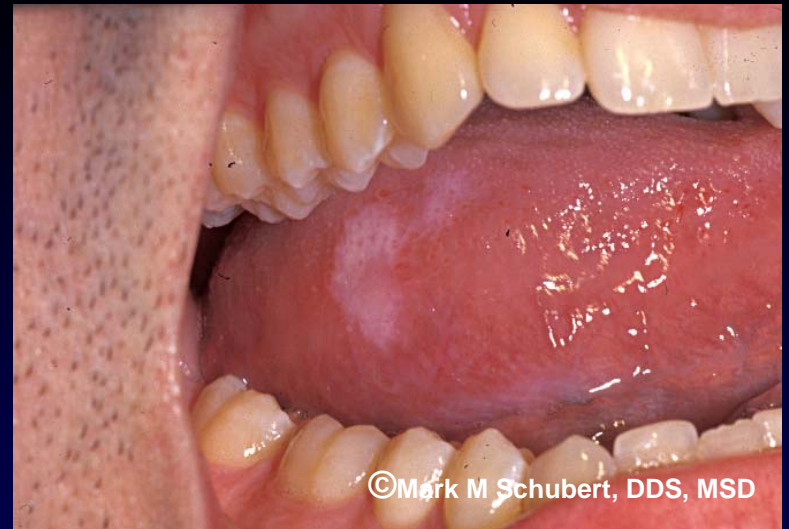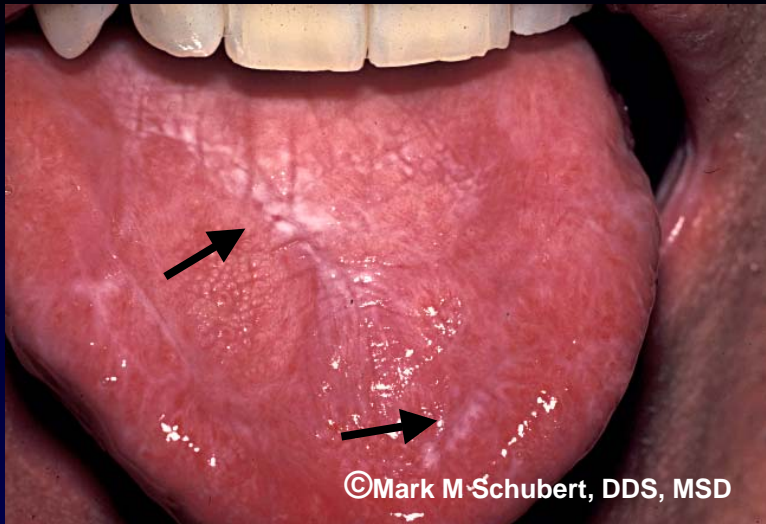


Lichenoid Hyperkeratosis

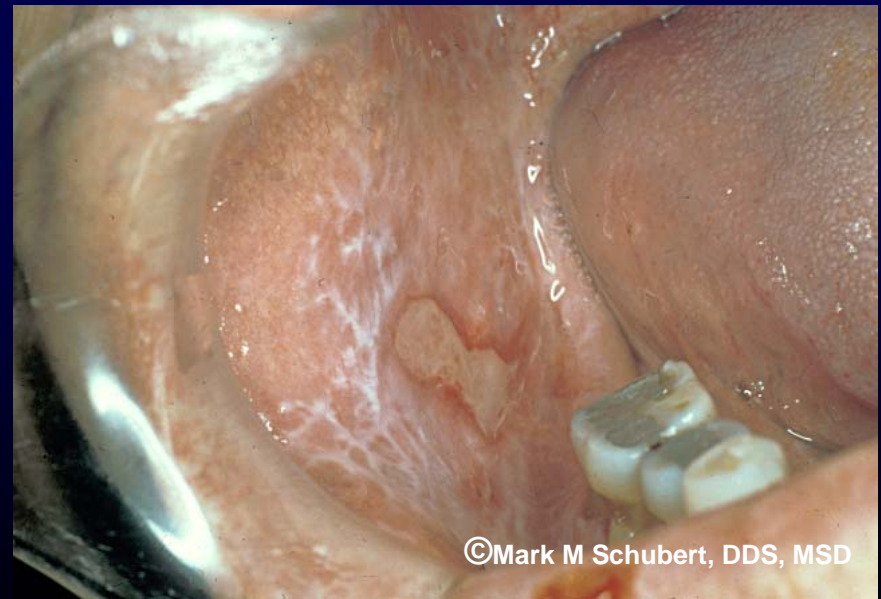
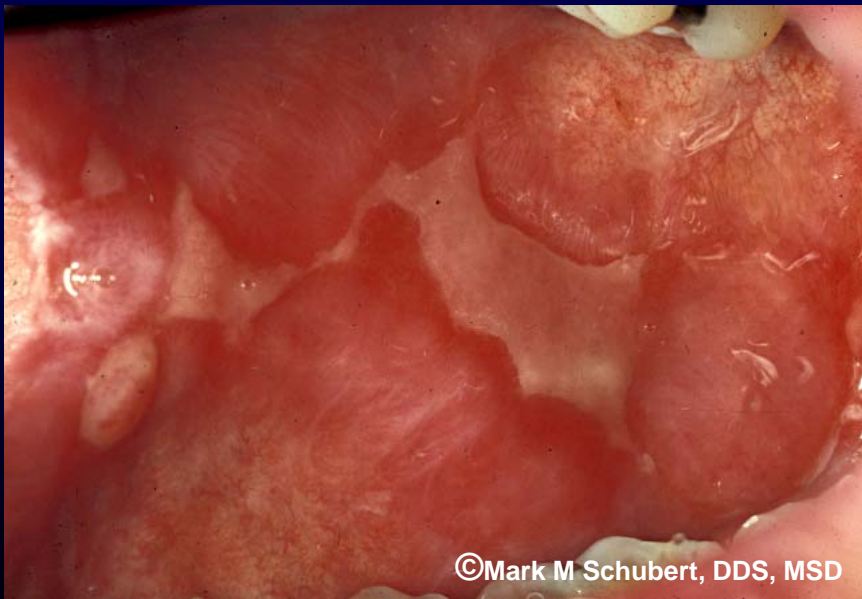




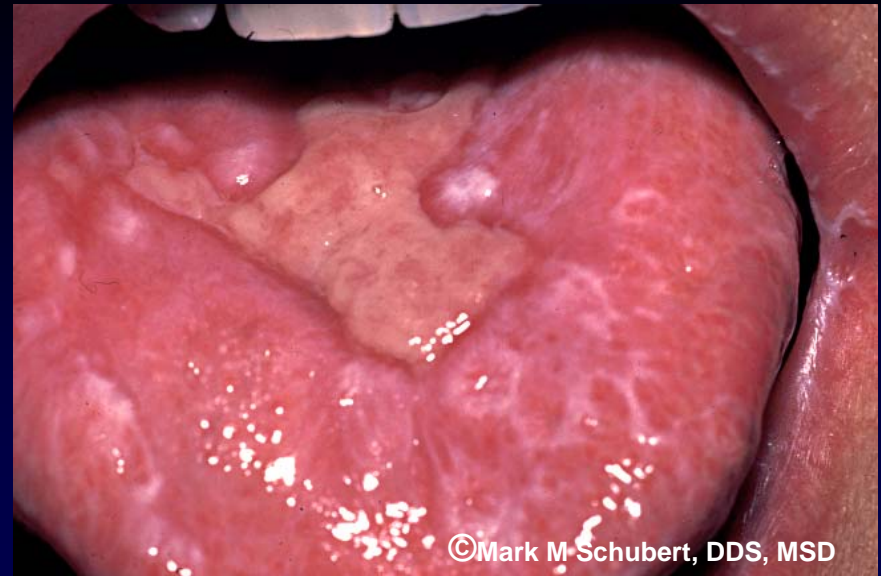
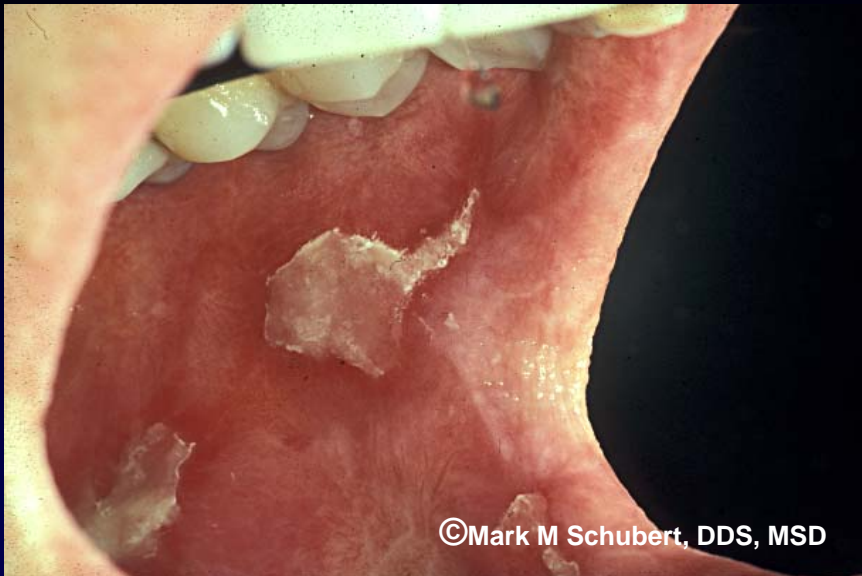Lichenoid Hyperkeratosis

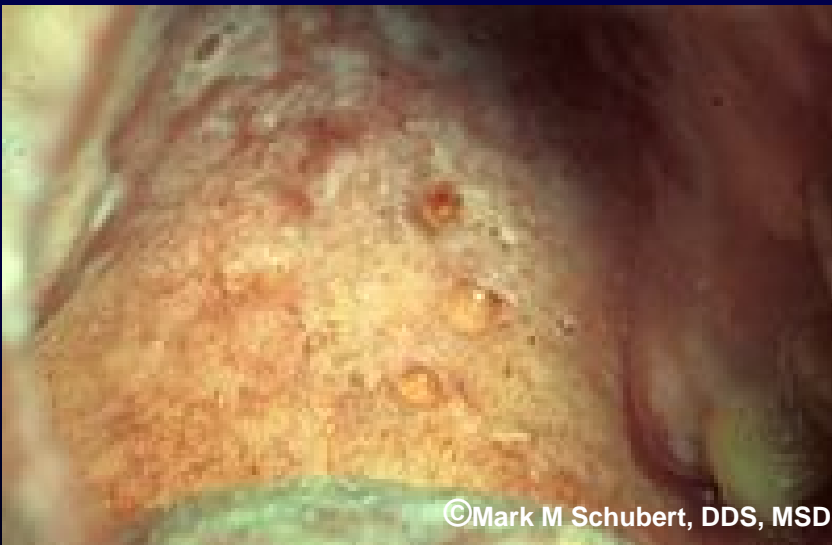

Lichenoid Hyperkeratosis

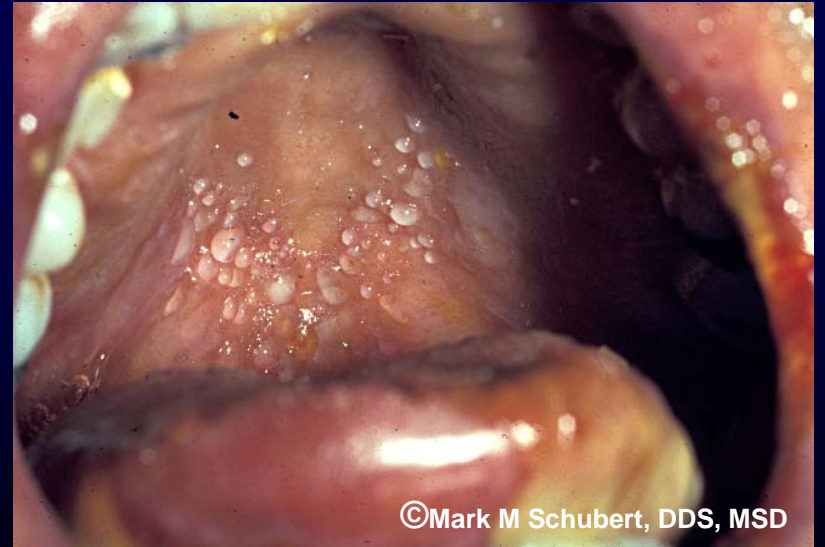


Pseudomembranous ulcerations with varying degrees of erythema and lichenoid hyperkeratotic changes



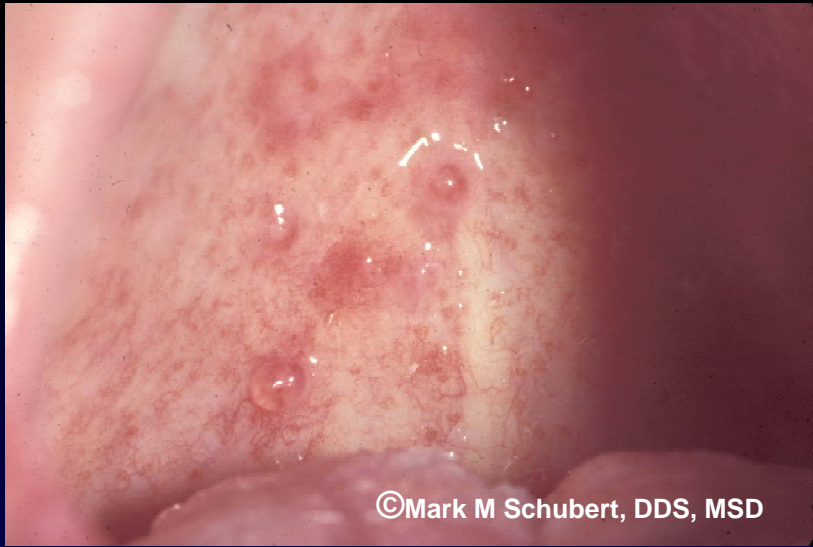


©Mark M Schubert, DDS, MSD

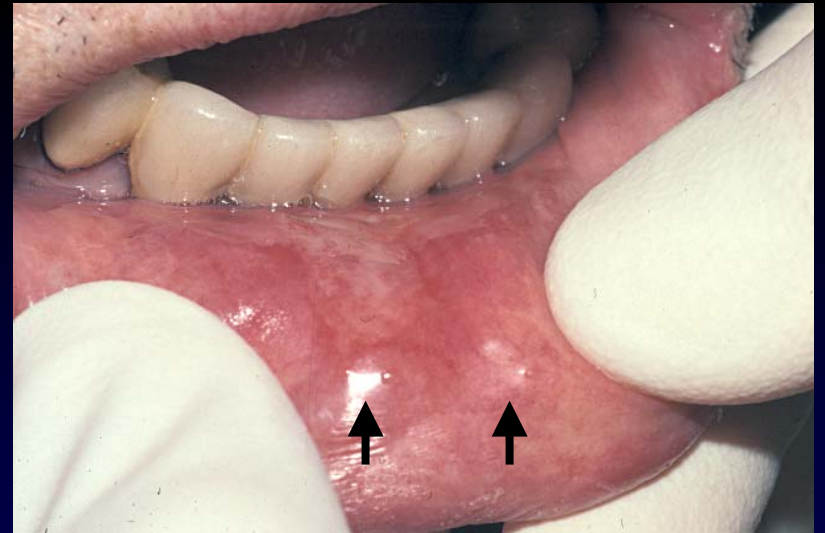


©Mark M Schubert, DDS, MSD

Mucoles caused by chronic GVHD



©Mark M Schubert, DDS, MSD



Mucoles caused by chronic GVHD

©Mark M Schubert, DDS, MSD